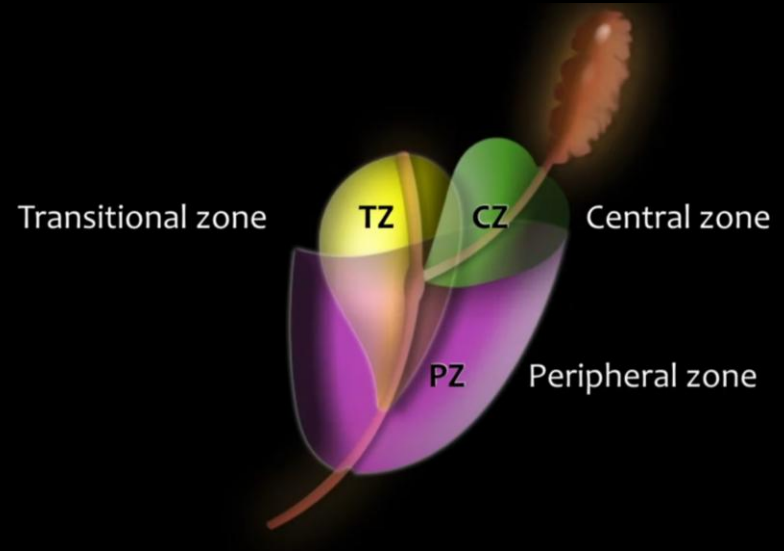
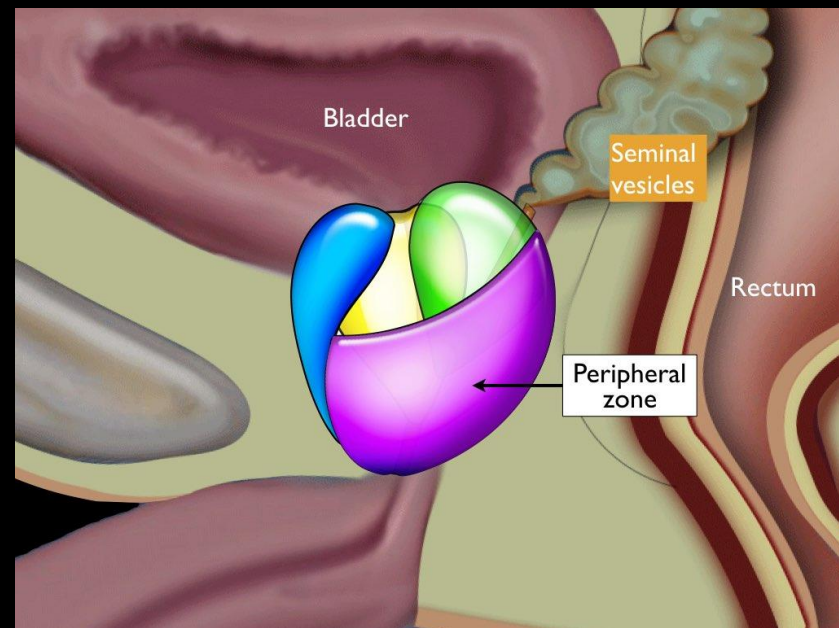
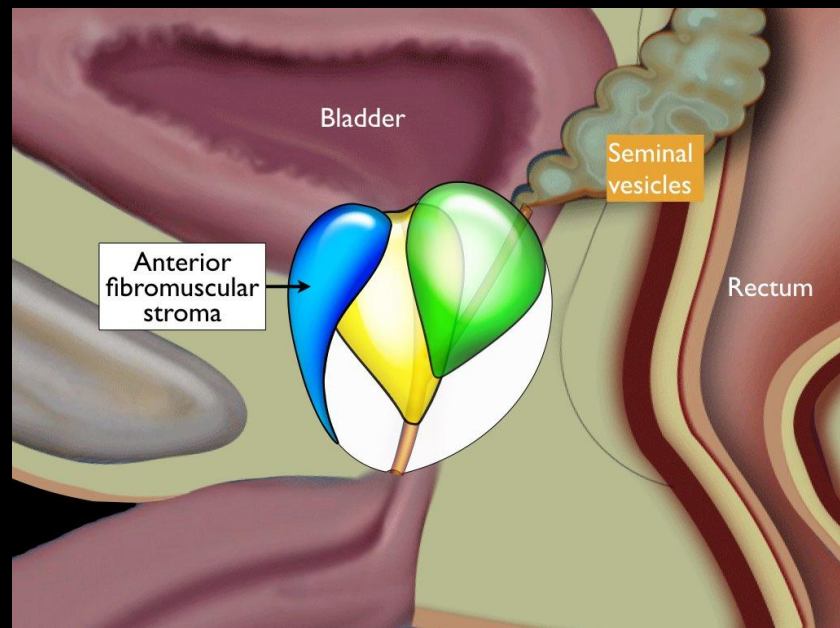
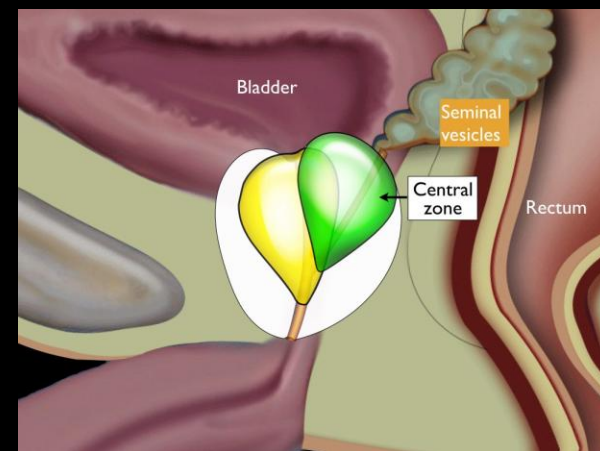
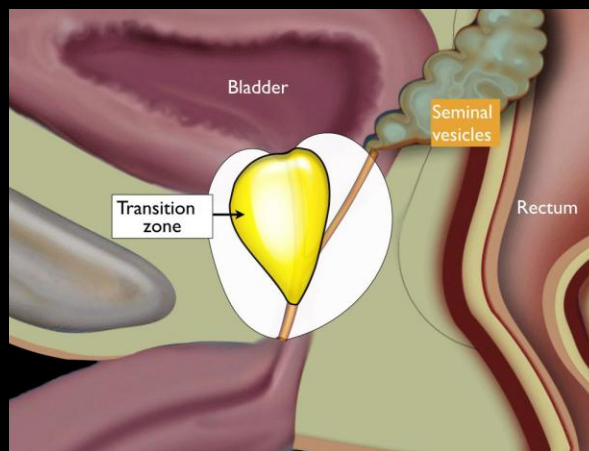
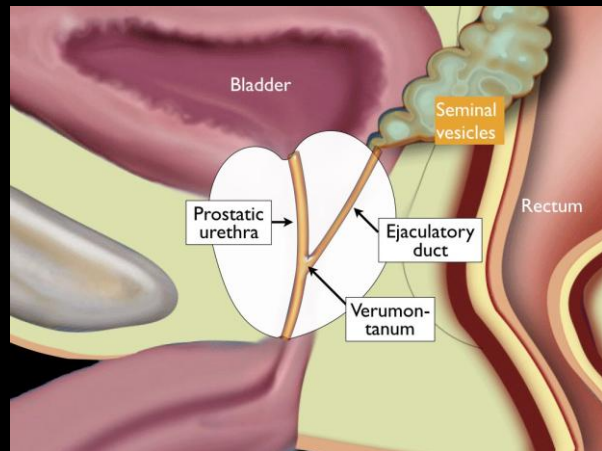
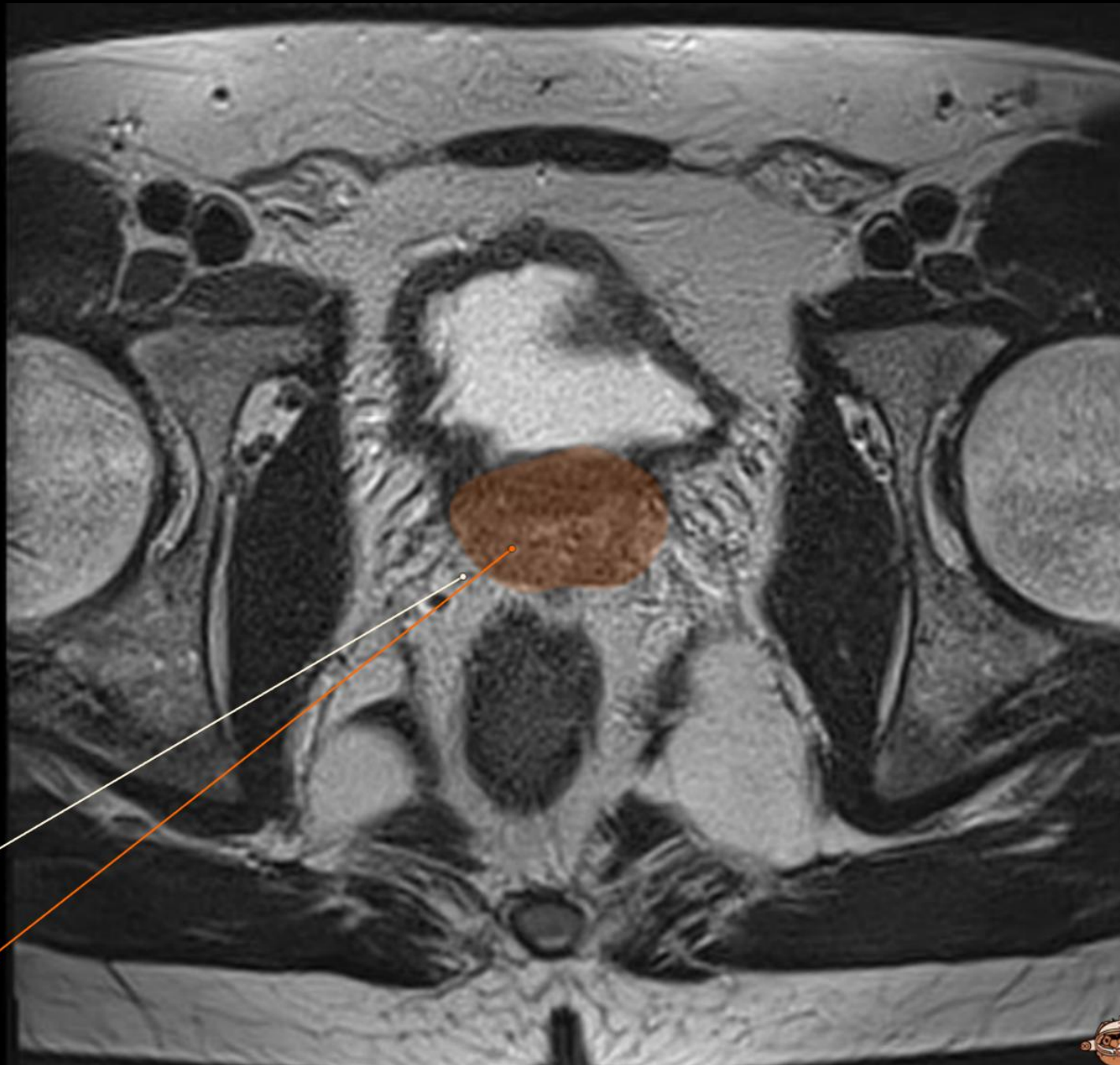

Zones

- **Transition zone**
 - Surrounds the prostatic urethra.
 - This zone enlarges in aging men resulting in benign prostatic hyperplasia.
- **Central zone**
 - lies in the base of the prostate behind the transition zone and surrounds the left and the right ejaculatory duct.
- **Anterior fibromuscular stroma**
 - Small area of tissue that is situated on the anterior side of the prostate.
- **Peripheral zone**
 - situated on the posterior and lateral side of the prostate.



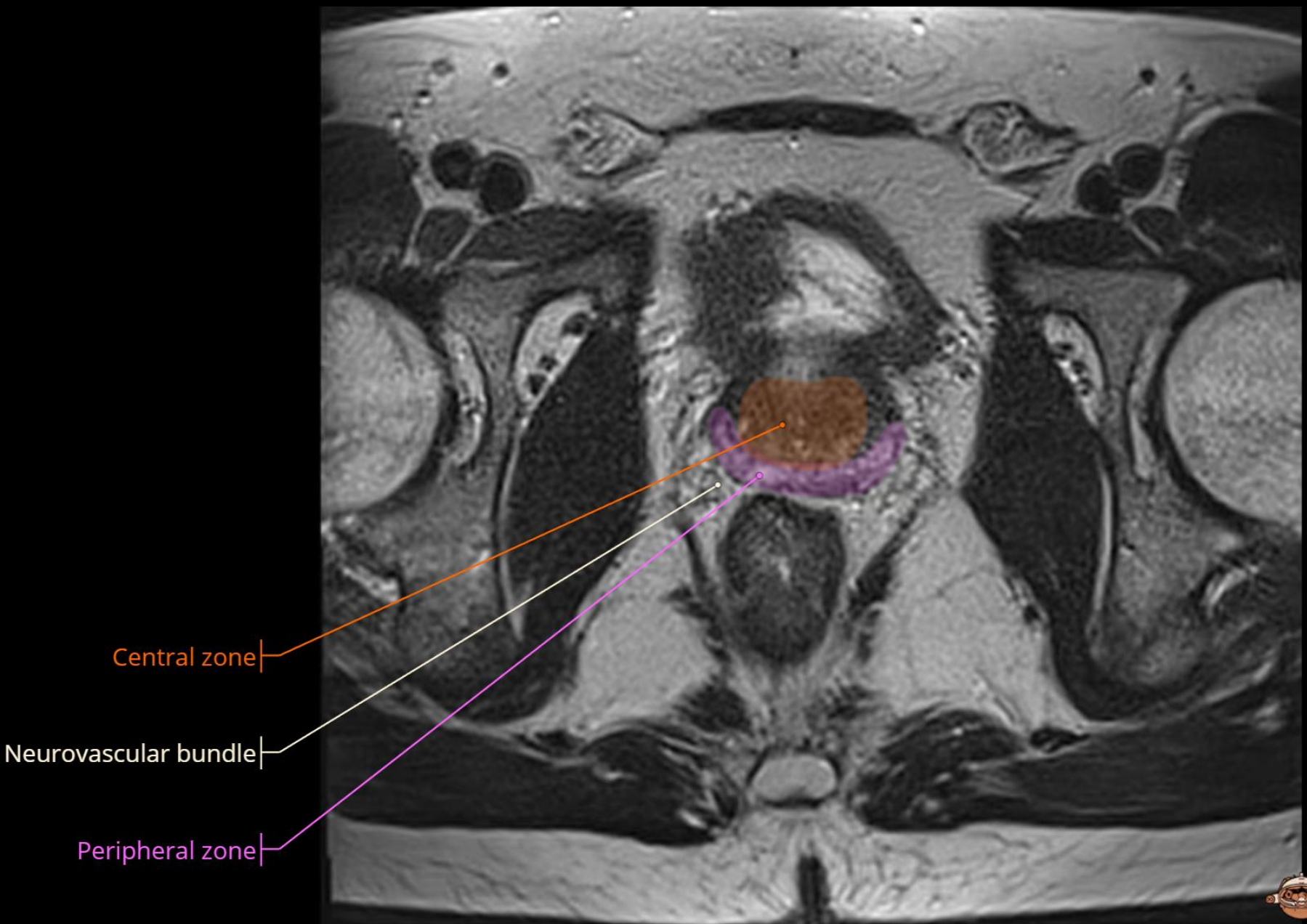




Neurovascular bundle

Central zone





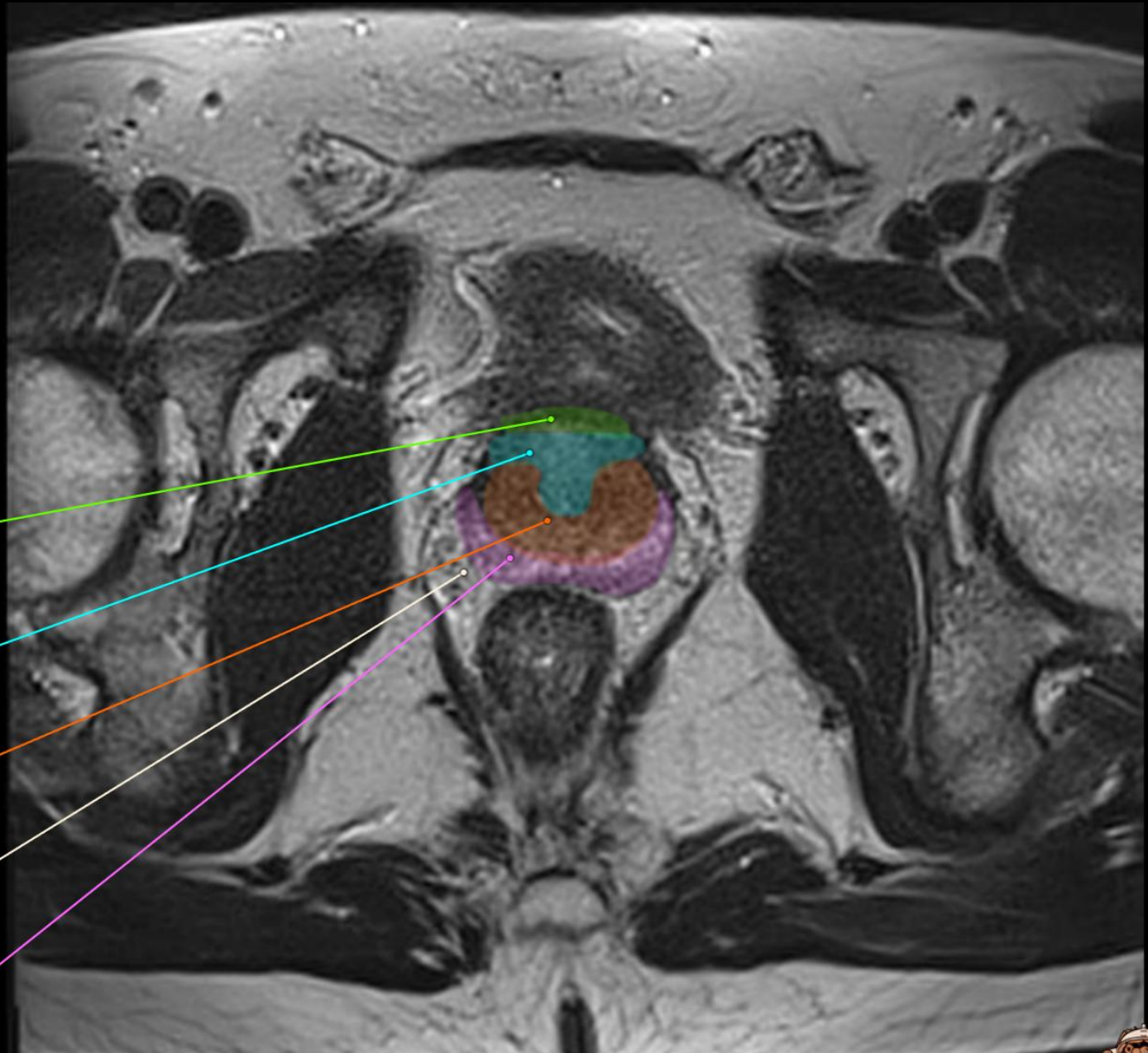
Anterior Fibromuscular
Stroma

Transition zone

Central zone

Neurovascular bundle

Peripheral zone



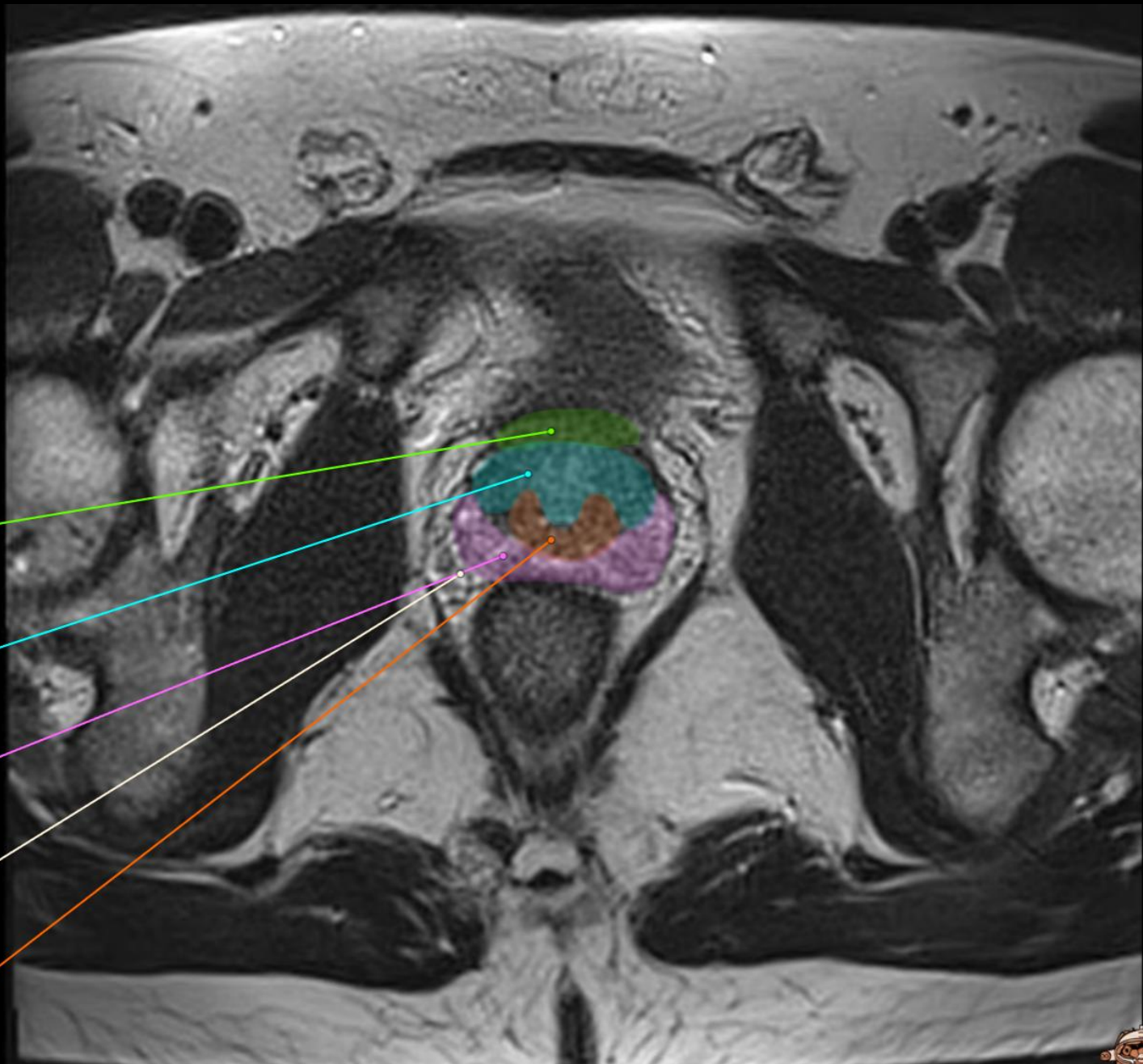
Anterior Fibromuscular
Stroma

Transition zone

Peripheral zone

Neurovascular bundle

Central zone



Anterior Fibromuscular
Stroma

Transition zone

Peripheral zone

Neurovascular bundle

